

Ovarian endometriomas and oocyte quality: insights from in vitro fertilization cycles

Francesca Filippi, M.D.,^a Laura Benaglia, M.D.,^a Alessio Paffoni, M.Sc.,^a Liliana Restelli, D.Sc.,^a Paolo Vercellini, M.D.,^{a,b} Edgardo Somigliana, M.D., Ph.D.,^a and Luigi Fedele, M.D.^{a,b}

^a Department of Obstetrics and Gynecology, Fondazione Ca' Granda, Ospedale Maggiore Policlinico; and ^b Università degli Studi di Milano, Milan, Italy

Objective: To evaluate whether the presence of endometriomas affects ovarian function.

Design: Prospective cohort study.

Setting: Infertility unit of an academic setting.

Patient(s): Twenty-nine women undergoing an IVF cycle.

Intervention(s): Prospective evaluation of women with unoperated unilateral endometriomas undergoing IVF. The affected and contralateral intact gonads were compared in terms of responsiveness and oocyte quality.

Main Outcome Measure(s): Oocyte developmental competence.

Results: Ovarian responsiveness and oocyte quality did not significantly differ between the affected and intact gonads. The number of codominant follicles, the number of oocytes retrieved, and the number of suitable oocytes in affected and intact gonads were 3.7 ± 2.4 and 4.1 ± 1.7 , 4.2 ± 3.1 and 4.7 ± 2.5 , and 3.1 ± 2.6 and 3.5 ± 2.3 , respectively. The number of viable embryos and the number of high-quality embryos were 1.8 ± 2.1 and 1.8 ± 1.4 and 1.0 ± 1.7 and 0.8 ± 0.7 , respectively. The fertilization rate in the affected and intact gonads was 64% and 64%, respectively. The cleavage rate was 58% and 51%, respectively. The rate of high-quality embryos was 31% and 21%, respectively.

Conclusion(s): In women undergoing IVF, the presence of ovarian endometriomas does not affect oocyte developmental competence. (Fertil Steril® 2014;101:988–93. ©2014 by American Society for Reproductive Medicine.)

Key Words: Endometrioma, IVF, oocyte

Discuss: You can discuss this article with its authors and with other ASRM members at <http://fertilityforum.com/filippif-ovarian-endometrioma-oocyte-ivf/>



Use your smartphone to scan this QR code and connect to the discussion forum for this article now.*

* Download a free QR code scanner by searching for "QR scanner" in your smartphone's app store or app marketplace.

There is currently a growing consensus that surgical excision of ovarian endometriomas may damage the ovarian reserve. Serum antimüllerian hormone (AMH) decreases after surgery (1, 2), and data from IVF cycles have consistently shown that ovarian responsiveness to hyperstimulation is markedly reduced in operated gonads (3). As a result, current efforts are aimed at improving the surgical technique, to better preserve the reserve in primordial

follicles of the affected gonads (4–6). Not surprisingly, expectant or medical management of women with ovarian endometriomas is gaining consensus (7).

A neglected and critical point is the presurgical endometrioma-mediated damage to the ovarian reserve. Demonstration of surgery-mediated injury does not exclude that the damage, at least in part, may also precede the intervention. However, the available data on this point are conflicting. On one hand, it has been repeatedly observed that the

ovarian cortex surrounding the endometriomas is altered when compared with other nonendometrioid benign ovarian cysts (8–13). On the other hand, this worrying evidence contrasts with the available clinical evidence suggesting that the damage is minimal (14–18). Of particular interest here is that two large, independent reports on ovarian responsiveness during IVF in women with unilateral endometriomas failed to document any significant difference between the affected and contralateral, intact gonads (19, 20). This study design (i.e., the use of women with unilateral disease undergoing IVF) is of utmost value because it allowed for the use of the same woman as her own control, thus protecting the results from

Received August 8, 2013; revised and accepted January 7, 2014; published online March 3, 2014. F.F. has nothing to disclose. L.B. has nothing to disclose. A.P. has nothing to disclose. L.R. has nothing to disclose. P.V. has nothing to disclose. E.S. has nothing to disclose. L.F. has nothing to disclose. Reprint requests: Francesca Filippi, M.D., Ospedale Maggiore Policlinico, Fondazione Ca' Granda, Infertility Unit, Via M. Fanti 6, 20122 Milan, Italy (E-mail: francesca.filippi@gmail.com).

Fertility and Sterility® Vol. 101, No. 4, April 2014 0015-0282/\$36.00
Copyright ©2014 American Society for Reproductive Medicine, Published by Elsevier Inc.
<http://dx.doi.org/10.1016/j.fertnstert.2014.01.008>

confounders. However, both of these studies were retrospective, and the available data were informative only in terms of the degree of responsiveness but not the quality of the oocytes. In fact, whereas in clinical practice the number of developing follicles and oocytes retrieved is recorded separately for the two ovaries, data on the subsequent embryo development cannot be retrieved retrospectively because the oocytes are typically handled without recording the ovary of origin. Moreover, oocyte retrieval may be affected by the presence of endometriomas, and follicles in the affected gonad may not be systematically aspirated. To overcome these limitations, we set up a prospective cohort study in women with unilateral ovarian endometriomas undergoing IVF. The main aim of the study was to determine whether the presence of the endometrioma affects oocyte developmental competence.

MATERIALS AND METHODS

Women selected for an IVF–intracytoplasmic sperm injection (ICSI) cycle at the Infertility Unit of the Fondazione Ca' Granda, Ospedale Maggiore Policlinico, Milan, Italy between January 2012 and March 2013 were prospectively evaluated for entry into the study. Eligible women included those with unilateral ovarian endometriomas who had not undergone previous ovarian surgery. More specifically, inclusion criteria were as follows: [1] age 18–42 years; [2] indication for IVF-ICSI; [3] presence of one or more unilateral ovarian endometriomas with a mean diameter <50 mm at transvaginal ultrasound; [4] no previous ovarian surgery; [5] no severe cause of male infertility (azoospermic cases requiring the use of spermatozoa obtained from surgical procedures, those with a sperm concentration <1 × 10⁶/mL, and those using frozen semen were excluded); [6] absence of nonendometriotic ovarian cysts; and [7] acceptance to participate. Women entering the study were subsequently excluded for the following circumstances: [1] cancelled oocyte retrieval for any reason (women failing to obtain viable embryos were conversely included); [2] freezing of some or all retrieved oocytes: this sometimes occurs in our unit because Italian legislation bans the use of an excessive number of oocytes; this exclusion criterion was decided to prevent the confounding effect that freezing procedures may have on the quality of the oocytes; and [3] accidental follicular fluid contamination with endometrioma content: these women were excluded because this event has already been reported to be potentially detrimental to the oocytes (21–23), and we were herein not interested in evaluating the impact of this complication, but rather we aimed at disentangling the impact of the proximity of ovarian endometriomas. Women were enrolled only for their first completed cycle performed during the study period. The study was accepted by the local institutional review board, and all participating women signed an informed consent form.

During the IVF-ICSI cycle, women were monitored and managed according to a standardized clinical protocol that was previously reported (24). Briefly, the patients underwent a baseline transvaginal ultrasound scan the month preceding the ovarian hyperstimulation. The presence of ovarian endome-

triomas and previous documentation of their presence was systematically recorded. Eligible women were recruited at this time. The regimen and the dose of gonadotropins were chosen on an individual basis on the basis of age, day-3 serum FSH, serum AMH, sonographic assessment of antral follicle count, and results from previous ovarian hyperstimulation cycles. During ovarian hyperstimulation the women underwent serial transvaginal ultrasound scans and serum estrogen and P assessments. Human chorionic gonadotropin (10,000 IU) was administered SC when the leading follicles had a mean diameter >18 mm. The total number of codominant follicles (i.e., those with a mean diameter >15 mm, calculated as the mean of three perpendicular diameters) per ovary was systematically recorded at this time. Oocyte retrieval was performed transvaginally 36 hours after hCG administration. All follicles with a mean diameter >10 mm were aspirated. All efforts were made to avoid follicular fluid contamination with the endometrioma content. However, if it was necessary to reach follicles located behind the endometrioma, the cyst could be transfixed. As mentioned above, contamination with endometrioma content was an exclusion criterion. Embryo transfer was performed 72 hours after oocyte collection. Cycles could be cancelled because of low or hyper-ovarian response. Cycles could be also cancelled after oocyte retrieval if the number of retrieved oocytes exceeded 15, in the presence of symptoms and signs suggestive for ovarian hyperstimulation syndrome, or if serum P exceeded 1,500 pg/mL at the time of hCG administration. In all of these situations, oocytes and/or embryos were frozen and used in subsequent cycles. However, these women were excluded from the present analysis. Clinical pregnancy was defined as the ultrasonographic demonstration of viable intrauterine embryos 4 to 5 weeks after embryo transfer.

Ovarian endometrioma was defined as a round-shaped cystic mass with a minimum diameter of 10 mm, with thick walls, regular margins, homogeneous low echogenic fluid content with scattered internal echoes, and without papillary projections (25). To rule out functional cysts, the presence of the endometriomas had to be documented on at least one previous ultrasound scan performed at least 2 months before the IVF-ICSI cycle. Atypical or doubtful cases were excluded. The diameters of the endometriomas were calculated as the mean of three perpendicular diameters.

Oocytes were evaluated using an inverted T200 microscope (Nikon). They were cultured and treated alone in every step of the assisted reproduction procedure to evaluate the characteristics of morphology, fertilization, and development and to successively correlate them with the ovary of origin. Morphologic evaluation was performed as previously reported (23). In the selected women, all the oocytes deemed suitable for fertilization were used. They were metaphase II oocytes (if ICSI was required) and type 1 cumulus–oocytes according to the European Society for Human Reproduction and Embryology Istanbul Consensus Conference (26) for IVF cycles. High-quality embryos were defined as types 1 and 2 embryos according to the current standard classification (26). Briefly, type 1 embryos have blastomeres of equal size and no cytoplasmic fragmentation, whereas type 2 embryos have blastomeres of equal size and minor cytoplasmic fragmentation (≤10% of the embryo surface). Embryos were evaluated separately by

TABLE 1

Baseline characteristics of the studied population (n = 29).

Characteristic	Mean \pm SD, median (IQR), or n (%)
Age (y)	35.9 \pm 4.0
BMI (kg/m ²)	22.0 \pm 2.6
Previous deliveries	4 (14)
Smoking	5 (17)
Duration of infertility (y)	3.9 \pm 2.1
Concomitant male factor of infertility	16 (55)
Previous IVF-ICSI cycles	6 (21)
Day-3 serum FSH (IU/mL)	7.8 \pm 2.5
AMH (ng/mL)	2.3 \pm 1.7
Antral follicle count (both ovaries)	10 (6–16)
Previous surgery for endometriosis ^a	3 (10)
Side of the endometriomas	
Right	14 (48)
Left	15 (52)
No. of endometriomas	
1	22 (76)
2	7 (23)
Mean diameter of the endometriomas (mm) ^b	25 \pm 9
CA-125 (IU/mL)	51 (23–64)
Medical treatment before entering the cycle	
Oral contraceptives	2 (7)
Progestins	6 (21)

^a Only women operated for nonovarian endometriosis could be included.

^b If more than one endometrioma was present, the data refer to the largest one.

Filippi. Endometrioma and oocyte quality. *Fertil Steril* 2014.

two of the authors (A.P. and L.R.), who were blinded to the ovary of origin. If discordant evaluations were given, the two biologists were asked to re-evaluate the case together to give a final judgment.

Analysis of the data was carried out using the Statistics Package for Social Sciences (version 18.0; SPSS). The analysis exclusively refers to fresh embryo transfer. Subsequent cycles using frozen embryos were not considered. The main outcome of the study was the rate of high-quality embryos (type 1 and 2) per oocyte used. Data are reported as number (percentage), mean \pm SD, or median (interquartile range [IQR]), as appropriate. The sample size was calculated on the basis of the following assumptions: [1] type I and II errors of 0.05 and 0.20, respectively; [2] rate of high-quality embryos expected in the unaffected ovary: 40% (27); [3] mean number of oocytes retrieved per ovary: >3 (27, 18); and [4] minimum difference to be regarded as clinically relevant: 20% (from 40% in the intact gonad to 20% in the affected one). On these bases, we needed at least 90 oocytes per ovary, which corresponded to approximately 30 women. An analysis per ovary was also performed using paired tests (paired Student *t* test or nonparametric Wilcoxon test for paired data). A *P* value ≤ 0.05 was considered statistically significant. A binomial distribution model was used to calculate the SD of the proportions.

RESULTS

The flow diagram of the study is shown in Supplemental Figure 1 (available online). Twenty-nine women were ultimately selected. They provided 91 suitable oocytes from the

affected ovary and 103 from the intact gonad, thus fulfilling our sample size minimal requirement. Baseline characteristics of the selected women are shown in Table 1. The mean \pm SD diameter of the endometriomas was 25 \pm 9 mm (range, 10–44 mm). The IVF-ICSI outcome is summarized in Table 2.

Ovarian responsiveness in the affected and contralateral intact gonads did not differ. Specifically, the number of codominant follicles, the number of oocytes retrieved, and the number of suitable oocytes were 3.7 \pm 2.4 and 4.1 \pm 1.7 (*P* = .54), 4.2 \pm 3.1 and 4.7 \pm 2.5 (*P* = .47), and 3.1 \pm 2.6 and 3.5 \pm 2.3 (*P* = .51) in the affected and contralateral intact gonads, respectively (paired Student *t* test). Similarly, we failed to document any significant difference when considering the embryos. The number of viable embryos and the number of high-quality embryos (type 1 and 2) were 1.8 \pm 2.1 and 1.8 \pm 1.4 (*P* = .00) and 1.0 \pm 1.7 and 0.8 \pm 0.7 (*P* = .53), respectively, using the paired Student *t* test. These results are shown in Figure 1.

The fertilization rate in the affected and intact gonads was 64% (58 of 91) and 64% (66 of 103; *P* = .96), respectively. The cleavage rate was 58% (53 of 91) and 51% (53 of 103; *P* = .34), respectively. The rate of high-quality embryos (type 1 and 2) per oocyte used was 31% (28 of 91) and 21% (22 of 103; *P* = .13), respectively. These results are illustrated in Figure 2. The crude relative risk of reaching a high-quality embryo from the oocytes obtained from the affected ovary was 1.28 (95% confidence interval 0.91–1.80, *P* = .13). The embryologic variables were also analyzed on a per-ovary basis using a paired analysis (nonparametric Wilcoxon test for paired data). The median (IQR) fertilization rates in the affected and intact gonads were 67% (0–94%) and 71% (36%–100%; *P* = .35), respectively. The median (IQR) cleavage rate was 58% (0–75%) and 50% (30%–73%; *P* = .75), respectively. The median (IQR) rate of high-quality embryos per oocyte used was 0 (0–42%) and 20% (0–32%; *P* = .93), respectively.

Data on the implantation rate could only be analyzed for women transferring embryos obtained exclusively from one of the two gonads. This occurred in 25 women, 10 of whom were transferred with embryos obtained from the affected ovary (15 embryos) and 15 from the intact one (23 embryos). The implantation rate was 40% (6 of 15) and 22% (5 of 23; *P* = .22), respectively.

DISCUSSION

In this prospective study we showed that in women with unilateral endometriomas undergoing IVF, developmental competence was similar for oocytes obtained from gonads with and without endometriomas. Our results expand upon previous evidence obtained in a similar population that demonstrated that ovarian responsiveness to hyperstimulation was not affected by the presence of ovarian endometriomas (19, 20).

Therefore, inconsistencies in reports on the impact of ovarian endometriomas on ovarian function deserve discussion. Two decades ago, Maneschi et al. (8) first reported experimental data supporting a detrimental effect of the presence of these cysts on the ovary. These authors evaluated the ovarian cortex surrounding dermoid cysts, cystadenomas, and

TABLE 2

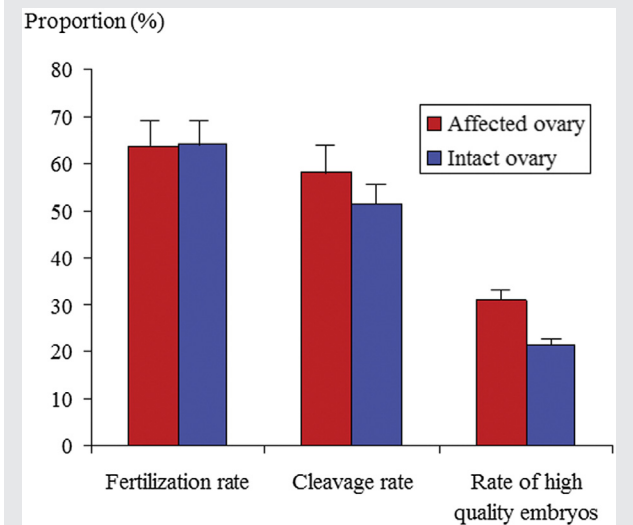
Outcome of IVF-ICSI in the studied population (n = 29).

Characteristic	Mean ± SD, median (IQR), or n (%)
Regimen of ovarian hyperstimulation	
Long protocol	21 (72)
Flare-up protocol	4 (14)
GnRH antagonists	4 (14)
Duration of stimulation (d)	10.6 ± 1.7
Total dose of FSH administered (IU)	2,736 ± 1,343
E ₂ at the time of hCG administration (pg/mL)	2,024 (1,600–2,953)
Total no. of oocytes retrieved	8.9 ± 4.4
Total no. of suitable oocytes ^a	6.7 ± 3.6
IVF technique used	
IVF	11 (38)
ICSI	18 (62)
Total no. of embryos	3.6 ± 2.7
Total no. of high-quality embryos	1.7 ± 1.9
No. of embryos transferred	
None (failed embryo transfer)	2 (7)
1	12 (41)
2	15 (53)
Clinical pregnancies (clinical pregnancy rate)	12 (41)
Embryos implanted (implantation rate)	12 (28)

^a Suitable oocytes corresponded to oocytes used. They were defined as metaphase II oocytes or type 1 cumulus–oocyte complexes according to the *European Society of Human Reproduction and Embryology Istanbul Consensus Conference* (23).

Filippi. Endometrioma and oocyte quality. *Fertil Steril* 2014.

FIGURE 2

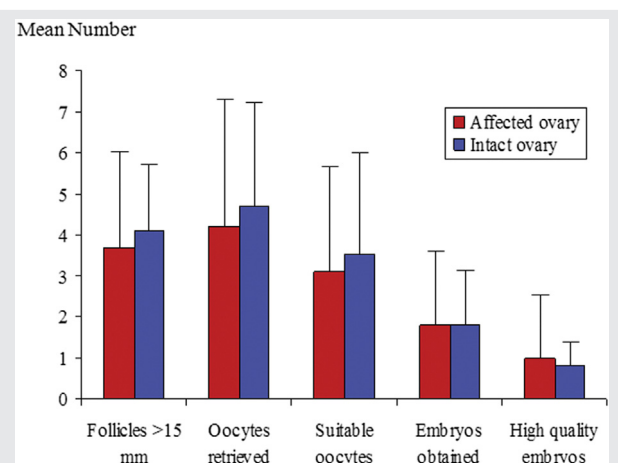


Embryologic outcome according to the ovary of origin. Red bars refer to oocytes obtained from the ovaries with the endometriomas. Blue bars refer to those obtained from the contralateral, intact gonads. The denominator is the number of oocytes used. No statistically significant differences emerged. The *P* values for the fertilization rate, the cleavage rate, and the rate of high-quality embryos were *P*=.96, *P*=.34, and *P*=.13, respectively (Fisher exact test). A binomial distribution model was used to calculate the SD of the proportions.

Filippi. Endometrioma and oocyte quality. *Fertil Steril* 2014.

endometriomas and observed a normal morphologic pattern in 92%, 77%, and 19% of the cases, respectively, and a normal vasculature network in 84%, 78%, and 22% of the cases, respec-

FIGURE 1



Number of follicles, oocytes retrieved, and embryos obtained according to the ovary of origin. Red bars refer to the ovaries with the endometriomas. Blue bars refer to the contralateral, intact gonads. No statistically significant differences emerged. The *P* values for the number of follicles, oocytes retrieved, suitable oocytes, embryos, and high-quality embryos were *P*=.54, *P*=.47, *P*=.51, *P*=1.00, and *P*=.53, respectively (paired Student *t* test). Data are presented as mean ± SD.

Filippi. Endometrioma and oocyte quality. *Fertil Steril* 2014.

tively. Several subsequent studies using different histologic approaches confirmed these findings (9–13). Overall, they documented that the density of primordial follicles is reduced and that the general morphology and vasculature network is distorted. Also of relevance is the observation that the amount of oxidative stress and reactive oxygen species (ROS) production in the ovarian cortex surrounding endometriomas is markedly higher than in other types of cysts (28–30). Immunostaining for 8-hydroxydeoxyguanosine, a DNA damage marker, was more than 10-fold greater in the ovarian cortex of women with endometriomas (28). On the basis of these studies, ROS production is unlikely to be the cause of the structural distortion because nonendometriotic cysts were used as controls. Conversely, it seems more likely that ROS may diffuse from the cyst, where they are present at extremely high concentrations (31). The presence of ROS in the ovarian tissue adjacent to endometriomas is of great interest because oxidative metabolism has been reported to be involved in every stage of ovarian follicle development and oocyte maturation, and ROS may negatively affect these processes (32–34).

On the other hand, the available clinical evidence is generally less dramatic. The main emerging view is that the impact of ovarian endometrioma on ovarian function and ovarian reserve is modest, at best. Two studies have reported on serum AMH in women with unoperated ovarian endometriomas. Uncu et al. (17) observed lower levels when they compared affected women with controls. However, Streuli et al. (16) reported on a significantly larger number of cases and did not document any difference. Two other studies

showed that, in women with unilateral unoperated endometriomas, spontaneous ovulation occurs less frequently in the affected gonad (14, 15). However, a recent larger study did not report any effect (35). Finally, two studies reported on IVF outcome in women with bilateral endometriomas. Reinblatt et al. (36) failed to document any effect, whereas our group documented a mild reduction in ovarian responsiveness but similar embryo development and pregnancy rates (18).

Drawing definitive conclusions based on these conflicting reports is difficult. We hypothesize that differences in the study outcomes and the populations studied may play a role. Furthermore, it should be pointed out that biological and histologic studies lack a clinical counterpart, and it may be argued that the detrimental effects emerging from these studies may actually be of little clinical relevance. In this regard, our data reporting on oocyte developmental competence should be considered of particular significance.

Some limitations of our study should be recognized. First, the main outcome chosen (i.e., the rate of type 1 and 2 embryos) may be a matter of concern. Even if embryos of high quality are widely considered as those with the highest chances to implant, we cannot rule out that this may not be entirely applicable to women with endometriomas. In other words, embryos obtained from affected gonads may be morphologically appropriate but intrinsically altered and unable to implant. Data from implantation rates would be more informative for determining this. In fact, we could only retrieve data on this outcome in a subgroup of women and embryos (15 embryos from affected ovaries and 23 embryos from intact ovaries) and no difference was observed. However, our study was underpowered to draw firm conclusions on this outcome. Evidence from larger studies performed within a policy of stringent single embryo transfer is required to properly address this issue. This study design would be particularly informative because it would provide the most reliable information on embryo quality (i.e., the rate of implantation), thus consenting to draw definite conclusions. It is worth noting that larger studies are also required to allow a per-ovary analysis. Indeed, in our study the rate of high-quality embryos was calculated by grouping all of the available oocytes, irrespective of the women of origin. A paired analysis on this rate per patient would be more appropriate to rule out confounders. In fact, we did this analysis and no difference emerged, but again, the study was underpowered to properly address this issue.

A second limitation of our study was the studied population. We exclusively included infertile women with an indication for IVF. Therefore, care should be used before applying our conclusions to all women with endometriomas. Selection of this subset of women may have biased the results in one of two ways. On one hand, we may have included less-severe cases. Selected women rarely reported a history of surgery for endometriosis before seeking pregnancy. Additionally, the size of the lesions was generally small, with a mean diameter of 25 mm. Of note, the mean diameter of the endometriomas in operated women is generally 40–50 mm (4, 37, 38). This selection bias may lead to an underestimation of the detrimental effects of endometriomas, especially if the

damage is related to overstretching of the ovarian cortex. On the other hand, because the selected women were infertile, we may have selected those for whom endometriomas actually impacted more on fertility and thus selected for lesions that were more detrimental. For the latter situation, our data would overestimate the impact. Given that we failed to detect any difference, this potential confounder would be irrelevant.

Finally, a third possible limitation is that we lacked a histologic diagnosis of endometriomas because the women in this study had not been operated on. However, we do not believe that this is an important limitation. The accuracy of sonographic diagnosis of endometriomas is well established. The sensitivity and specificity of transvaginal ultrasound have been reported to be 84%–100% and 90%–100%, respectively (25). Accordingly, this instrument has been used in several previous studies on nonoperated endometriomas (14, 15, 18–20, 39). Moreover, in our study, diagnoses were exclusively made by expert physicians, atypical cases were excluded, and we included only women with a sonographic demonstration of endometriomas on at least two occasions that were at least 2 months apart, thus protecting our data from the risk of erroneously including women with functional ovarian cysts.

In conclusion, our findings suggest that, in women undergoing IVF cycles, ovarian endometriomas do not affect oocyte developmental competence. Evidence from larger studies and using different experimental approaches is, however, required to definitely rule out any effect of ovarian endometriomas on ovarian function and ovarian reserve.

REFERENCES

- Raffi F, Metwally M, Amer S. The impact of excision of ovarian endometrioma on ovarian reserve: a systematic review and meta-analysis. *J Clin Endocrinol Metab* 2012;97:3146–54.
- Somigliana E, Berlanda N, Benaglia L, Viganò P, Vercellini P, Fedele L. Surgical excision of endometriomas and ovarian reserve: a systematic review on serum antimüllerian hormone level modifications. *Fertil Steril* 2012;98:1531–8.
- Somigliana E, Benaglia L, Viganò P, Candiani M, Vercellini P, Fedele L. Surgical measures for endometriosis-related infertility: a plea for research. *Placenta* 2011;32(Suppl 3):S238–42.
- Donnez J, Lousse JC, Jadoul P, Donnez O, Squifflet J. Laparoscopic management of endometriomas using a combined technique of excisional (cystectomy) and ablative surgery. *Fertil Steril* 2010;94:28–32.
- Kondo W, Darai E, Yazbeck C, Panel P, Tamburro S, Dubuisson J, et al. Do patients manage to achieve pregnancy after a major complication of deeply infiltrating endometriosis resection? *Eur J Obstet Gynecol Reprod Biol* 2011; 154:196–9.
- Ferrero S, Venturini PL, Gillott DJ, Remorgida V, Leone Roberti Maggiore U. Hemostasis by bipolar coagulation versus suture after surgical stripping of bilateral ovarian endometriomas: a randomized controlled trial. *J Minim Invasive Gynecol* 2012;19:722–30.
- Garcia-Velasco JA, Somigliana E. Management of endometriomas in women requiring IVF: to touch or not to touch. *Hum Reprod* 2009;24: 496–501.
- Maneschi F, Marasá L, Incandela S, Mazzarese M, Zupi E. Ovarian cortex surrounding benign neoplasms: a histologic study. *Am J Obstet Gynecol* 1993; 169:388–93.
- Muzii L, Bianchi A, Croce C, Mancini N, Panici PB. Laparoscopic excision of ovarian cysts: is the stripping technique a tissue-sparing procedure? *Fertil Steril* 2002;77:609–14.

10. Schubert B, Canis M, Darcha C, Artonne C, Pouly JL, Dechelotte P, et al. Human ovarian tissue from cortex surrounding benign cysts: a model to study ovarian tissue cryopreservation. *Hum Reprod* 2005;20:1786–92.
11. Shi J, Leng J, Cui Q, Lang J. Follicle loss after laparoscopic treatment of ovarian endometriotic cysts. *Int J Gynaecol Obstet* 2011;115:277–81.
12. Kitajima M, Defrere S, Dolmans MM, Colette S, Squifflet J, Van Langendonck A, et al. Endometriomas as a possible cause of reduced ovarian reserve in women with endometriosis. *Fertil Steril* 2011;96:685–91.
13. Kuroda M, Kuroda K, Arakawa A, Fukumura Y, Kitade M, Kikuchi I, et al. Histological assessment of impact of ovarian endometrioma and laparoscopic cystectomy on ovarian reserve. *J Obstet Gynaecol Res* 2012;38:1187–93.
14. Horikawa T, Nakagawa K, Ohgi S, Kojima R, Nakashima A, Ito M, et al. The frequency of ovulation from the affected ovary decreases following laparoscopic cystectomy in infertile women with unilateral endometrioma during a natural cycle. *J Assist Reprod Genet* 2008;25:239–44.
15. Benaglia L, Somigliana E, Vercellini P, Abbiati A, Ragni G, Fedele L. Endometriotic ovarian cysts negatively affect the rate of spontaneous ovulation. *Hum Reprod* 2009;24:2183–6.
16. Streuli I, de Ziegler D, Gayet V, Santulli P, Bijaoui G, de Maouzon J, et al. In women with endometriosis anti-Mullerian hormone levels are decreased only in those with previous endometrioma surgery. *Hum Reprod* 2012;27:3294–303.
17. Uncu G, Kasapoglu I, Ozerkan K, Seyhan A, Oral Yilmaztepe A, Ata B. Prospective assessment of the impact of endometriomas and their removal on ovarian reserve and determinants of the rate of decline in ovarian reserve. *Hum Reprod* 2013;28:2140–5.
18. Benaglia L, Bermejo A, Somigliana E, Faulisi S, Ragni G, Fedele L, et al. In vitro fertilization outcome in women with unoperated bilateral endometriomas. *Fertil Steril* 2013;99:1714–9.
19. Almog B, Shehata F, Shezaf B, Tan SL, Tulandi T. Effects of ovarian endometrioma on the number of oocytes retrieved for in vitro fertilization. *Fertil Steril* 2011;95:525–7.
20. Benaglia L, Pasin R, Somigliana E, Vercellini P, Ragni G, Fedele L. Unoperated ovarian endometriomas and responsiveness to hyperstimulation. *Hum Reprod* 2011;26:1356–61.
21. Suwajanakorn S, Pruksananonda K, Sereepapong W, Ahnonkitpanit V, Chompurat D, Boonkasemsanti W, et al. Effects of contaminated endometriotic contents on quality of oocytes. *J Med Assoc Thai* 2001;84(Suppl 1):S371–6.
22. Khamis F, Yavas Y, Lacanna IC, Roberge S, Endman M, Wong JC. Exposure of human oocytes to endometrioma fluid does not alter fertilization or early embryo development. *J Assist Reprod Genet* 2001;18:106–9.
23. Piromlertamorn W, Saeng-Anan U, Vutyavanich T. Effects of ovarian endometriotic fluid exposure on fertilization rate of mouse oocytes and subsequent embryo development. *Reprod Biol Endocrinol* 2013;11:4.
24. Somigliana E, Paffoni A, Busnelli A, Cardellicchio L, Leonardi M, Filippi F, et al. IVF outcome in poor responders failing to produce viable embryos in the preceding cycle. *Reprod Biomed Online* 2013;26:569–76.
25. Savelli L. Transvaginal sonography for the assessment of ovarian and pelvic endometriosis: how deep is our understanding? *Ultrasound Obstet Gynecol* 2009;33:497–501.
26. Alpha Scientists in Reproductive Medicine and ESHRE Special Interest Group of Embryology. The Istanbul consensus workshop on embryo assessment: proceedings of an expert meeting. *Hum Reprod* 2011;26:1270–83.
27. Ragni G, Somigliana E, Benedetti F, Paffoni A, Vegetti W, Restelli L, et al. Damage to ovarian reserve associated with laparoscopic excision of endometriomas: a quantitative rather than a qualitative injury. *Am J Obstet Gynecol* 2005;19:1908–14.
28. Matsuzaki S, Schubert B. Oxidative stress status in normal ovarian cortex surrounding ovarian endometriosis. *Fertil Steril* 2010;93:2431–2.
29. Jana SK, K NB, Chattopadhyay R, Chakravarty B, Chaudhury K. Upper control limit of reactive oxygen species in follicular fluid beyond which viable embryo formation is not favorable. *Reprod Toxicol* 2010;29:447–51.
30. Karuputhula NB, Chattopadhyay R, Chakravarty B, Chaudhury K. Oxidative status in granulosa cells of infertile women undergoing IVF. *Syst Biol Reprod Med* 2013;59:91–8.
31. Agarwal A, Aponte-Mellado A, Premkumar BJ, Shaman A, Gupta S. The effects of oxidative stress on female reproduction: a review. *Reprod Biol Endocrinol* 2012;10:49.
32. Pasqualotto EB, Agarwal A, Sharma RK, Izzo VM, Pinotti JA, Joshi NJ, et al. Effect of oxidative stress in follicular fluid on the outcome of assisted reproductive procedures. *Fertil Steril* 2004;81:973–6.
33. Zhang X, Li XH, Ma X, Wang ZH, Lu S, Guo YL. Redox-induced apoptosis of human oocytes in resting follicles invitro. *J SocGynecol Investig* 2006;13:451–8.
34. Tamura H, Takasaki A, Miwa I, Taniguchi K, Maekawa R, Asada H, et al. Oxidative stress impairs oocyte quality and melatonin protects oocytes from free radical damage and improves fertilization rate. *J Pineal Res* 2008;44:280–7.
35. Scala C, Leone Roberti Maggiore U, Tafi E, Racca A, Venturini PL, Remorgida V, et al. Endometriotic ovarian cysts do not negatively affect the rate of spontaneous ovulation. *Hum Reprod* 2013;29(Suppl 1):13–4.
36. Reinblatt SL, Ishai L, Shehata F, Son WY, Tulandi T, Almog B. Effects of ovarian endometrioma on embryo quality. *Fertil Steril* 2011;95:2700–2.
37. Matsuzaki S, Houle C, Darcha C, Pouly JL, Mage G, Canis M. Analysis of risk factors for the removal of normal ovarian tissue during laparoscopic cystectomy for ovarian endometriosis. *Hum Reprod* 2009;24:1402–6.
38. Seracchioli R, Mabrouk M, Frascà C, Manuzzi L, Montanari G, Keramyda A, et al. Long-term cyclic and continuous oral contraceptive therapy and endometrioma recurrence: a randomized controlled trial. *Fertil Steril* 2010;93:52–6.
39. Vercellini P, Somigliana E, Vigano P, Abbiati A, Barbara G, Fedele L. 'Blood On The Tracks' from corpora lutea to endometriomas. *BJOG* 2009;116:366–71.

SUPPLEMENTAL FIGURE 1

